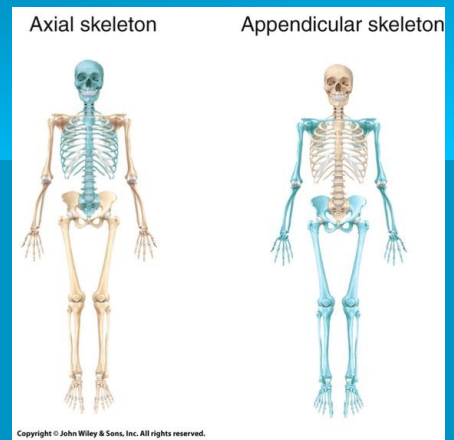
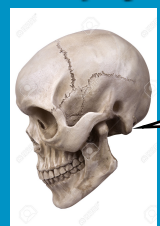

Skeletal System



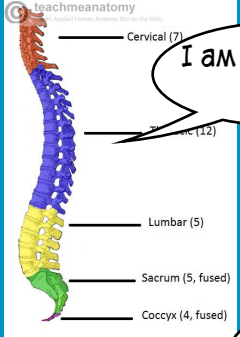
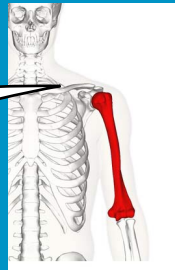
Axial skeleton - cranium, ribs, vertebrae,
Appendicular skeleton - the rest of the limbs

TYPES OF BONE



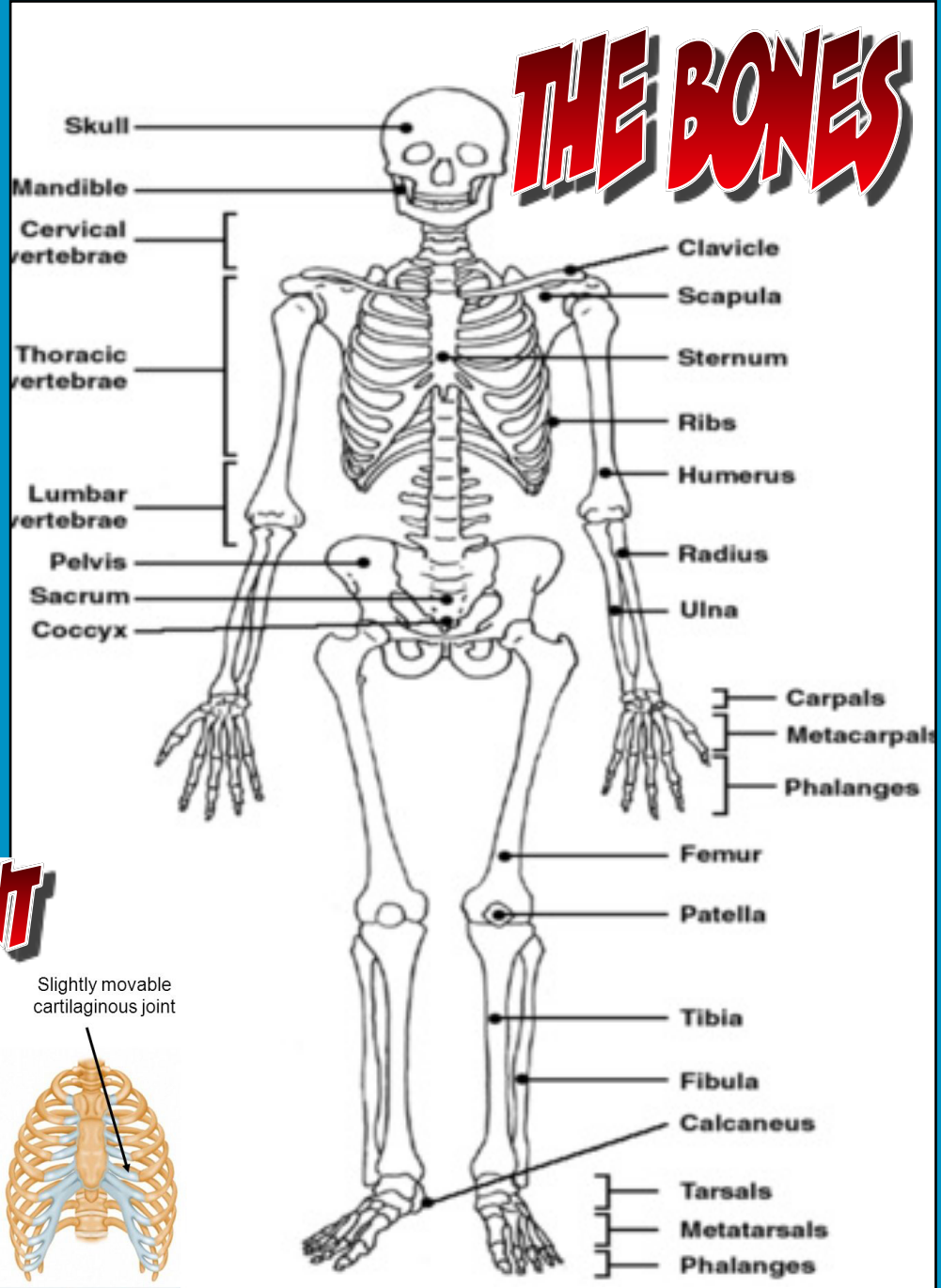
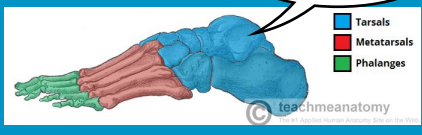
I am a flat bone

I am a long bone



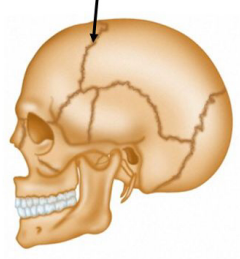
I am an irregular bone

I am a long bone

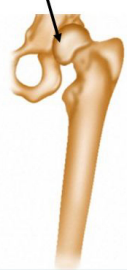

TYPES OF JOINT

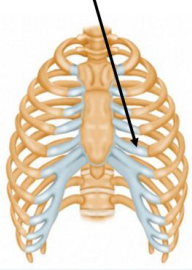
Immovable fibrous joint



Movable synovial joint



Slightly movable cartilaginous joint



Wellcome Images

Wellcome Photo Library